Quest International Journal of Medical and Health Sciences – [Online]

ORIGINAL ARTICLE

Variations of the number of papillary muscles of the right ventricle: A study from Bangladesh

Lubna Shirin[1*], Mohammed Shahjahan Kabir[2], Aaijaz Ahmed Khan[3], Amardev Singh Thanu Karnail Singh[4], Humaira Naushaba[5], Tahamina Begum[6]

Corresponding author:

[1]Dr. Lubna Shirin, MBBS, MPhil., Senior Lecturer, Department of Anatomy, Faculty of Medicine, QIU, Malaysia
Email: lubna.shirin@qiup.edu.my [ORCID]

[2]Mohammed Shahjahan Kabir, MBBS, MD, Associate Professor, Department of Medicine [ORCID]

[3]Aaijaz Ahmed Khan, MBBS, MD, Associate Professor and HOD, Department of Anatomy [ORCID]

[4]Amardev Singh Thanu Karnail Singh, MBBS, MD, Lecturer, Department of Anatomy [ORCID]

[5]Humaira Naushaba, MBBS, MPhil, Professor and HOD Department of Anatomy, Green Life Medical College and Hospital, Dhaka, Bangladesh

[6]Tahamina Begum, MBBS, Ph.D. (Neurophysiology) Department of Neurosciences, School of Medical Sciences, Universiti Sains Malaysia, 16150 Kubang Kerian, Kota Bharu, Kelantan, Malaysia [ORCID]

[1-4]Faculty of Medicine, Quest International University (QIU), No.227, Plaza Teh Teng Seng (Level 2), Jalan Raja Permaisuri Bainun, 30250 Ipoh, Perak Darul Ridzuan, Malaysia

Information about the article:

Received: Sep. 12 2020
Accepted: Dec. 15, 2020
Published online: Dec. 31, 2020

Publisher

Quest International University (QIU), No.227, Plaza Teh Teng Seng (Level 2), Jalan Raja Permaisuri Bainun, 30250 Ipoh, Perak Darul Ridzuan, Malaysia

e-ISSN: 2636-9478
© The Author(s). 2020
Content licensing: CC BY 4.0

ABSTRACT

Introduction:
Papillary muscles (PM) are an important component of ventricular musculature of the heart. PM is a myocardial projection significant for the proper working of the atrioventricular (AV) valve. The present study focused to document the variations of anterior papillary muscles (APM), posterior (PPM) and septal papillary muscles (SPM) in the right ventricle.

Methods:
We studied apparently normal post-mortem hearts (n=60) which were grouped as "group A" (n=41, 68.33%) and "group B" (n=19, 31.66%) based on males and females respectively. The age of the samples of hearts, ranged from 20-70 years, were collected from the department of forensic Medicine of Dhaka Medical College (DMC) and Sir Salimullah Medical College (SSMC). The SPSS 22.0 version was used for the statistical analysis of this study and unpaired t -the test was administered to observe the difference between two groups in relation to gender.

Results:
A single number of APM was most frequent in both groups (M: F = 85%:68%) whereas double numbers of PPM were identified in about 53% of both genders. (M: F = 85%:68%). Remarkably abundant pattern of SPM was 3 in number (M: F = 47%:68%). The highest number of papillary muscles discovered, were 4 in number which belonged to PPM (10%) and SPM (11%) for "group A" and "group B" respectively.

Conclusion:
The present study gave us a baseline data concerning variations of the number of papillary muscles of the right ventricle in the Bangladeshi population. It provides information to physicians for the diagnosis and management of different cardiac diseases involving papillary muscles.

Keywords
Bangladesh, papillary muscle, population, right ventricle, tricuspid valve

Introduction

Papillary muscles (PM) are an important component of the musculature of the ventricles of the heart. PM is a conical muscular projection of myocardium used for the proper working of the atrioventricular (AV) valve. On the basis of location, the types of papillary muscles in the right ventricle are the anterior papillary muscle (APM), the posterior papillary muscle (PPM) [1],besides this minor septal papillary muscle (SPM), is a smaller and variable attached with the ventricular septum [2] whereas the left ventricle has APM and PPM.[1] APM is large and arises from the atrioventricular wall, the posterior papillary which is bifid or trifid arises below the infero-septal commissure and small septal muscle arise from the posterior limb of the septomarginal trabeculae. [3]

Anatomical variations of the tricuspid and mitral valves, number, length, breadth including shapes of the papillary muscles and their chordae tendineae are associated with congenital abnormalities and syndrome like rheumatic heart disease, papillary muscle dysfunction and mitral valve prolapse. The papillary muscles of the right ventricle have a clinically significant role in contraction as well as opening of tricuspid valve, they prevent the regurgitation of ventricular blood into the right atrium. [4]

The significance of PM variations in the left ventricle found in earlier studies concerned with rheumatic heart disease, papillary muscle dysfunction, mitral valve prolapses, valve reparative procedures including mitral valve replacement and the use of mitral valve homograft for mitral/tricuspid replacement. [5-7] Anatomical variations of the right atrioventricular valve, the number and morphology of the papillary muscles, as well as associated chordae tendineae is important in congenital anomalies and syndromes. Intractable arrhythmia normally arises from the papillary muscle and surgical correction is required. [8] The lack of clinical and surgical importance of the papillary muscle and its anatomical features makes it a potential risk factor which leads to sudden deaths.

The morphological variety of the number of papillary muscles mentioned in the textbooks are predominantly based on western population whereas, in the Asian population and developing countries such as Bangladesh, India, and Pakistan are relatively less. These variations are also dissimilar among the human groups of people of different geographical regions. The Bangladeshi's may have their own range of variations. To our knowledge, studies on the papillary muscles of the tricuspid valve complex of fresh formalin-fixed hearts of the Bangladeshi adult population of both genders are deficient. This present study will enrich our knowledge and help us to differentiate the Bangladeshi's with the western population which may enlighten different therapeutic interventions in the field of medicine.

Methods

Study design and collection of data

This descriptive study was conducted in the Department of Anatomy of SSMC, Dhaka, Bangladesh.

Dissection method

Dissection of the cadaver was performed according to standard autopsy techniques, and heart specimens were collected within 12-36 hours of death (age 20-70 years), from the archive of the department of forensic Medicine of DMC and SSMC further they were preserved in 10% formal saline. Based on gender the collected specimens were divided into following groups: Group-A include forty-one males (n=41), and group-B includes nineteen females (n=19). The heart was opened by an incision from the right atrium to the apex of the heart through the acute margin of the ventricle. Another incision was also done from the apex to the annulus along ventral surface of the heart and was a bit left lateral to the intra-ventricular groove. With the help of the divider exposed the interior structure and observed the number of the papillary muscles.

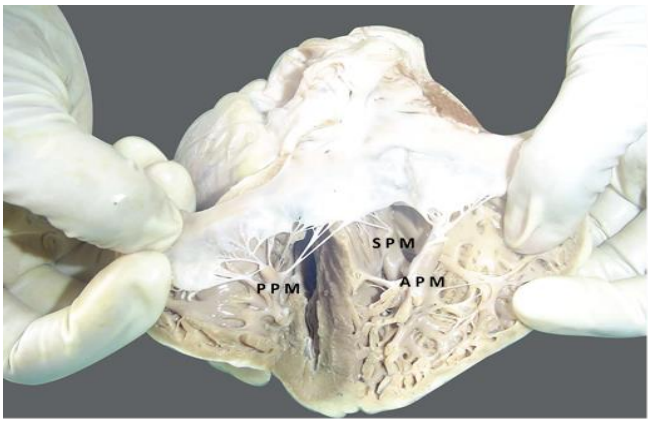

Figure 1: A photograph of this section shows the right ventricle of the heart through the interventricular septum showing APM, PPM and SPM of the right ventricle.

Inclusion criteria

Apparently, normal adult human hearts obtained from (n=60) in the department of forensic medicine of SSMC and DMC, Dhaka Bangladesh were included.

Exclusion criteria

Putrefied heart, death due to poisoning, most apparently affected with diseased heart and congenital cardiac anomalies were set up as exclusion criteria.

Ethical committee approval

Ethical approval was obtained from the Medical Research and Ethical committee (MREC) of SSMC.

Data management and statistical analysis

The data was collected systematically and analyzed by using IBM Statistical package for social sciences Windows, SPSS 22.0 version.

Results

a. Number of the APM

Table 1 and figure 2 shows 85% 1, 12% 2 and 3% 3 APM in males and 68% 1, 21% 2 and 11% 3 APM in females. Statistically there was no significant difference (P > 0.05) in the number of APM between the two groups.

Table 1: Distribution of the number of APM, PPM and SPM in male and females n (%)

Gender	Type and no of Papillary Muscles	Type 1	Type 2	Type 3	Type 4	P value
Male	APM	35(85)	5(12)	1(3)	0(0)	0.1[x]
Female		13(68)	4(21)	2(11)	0(0)	
Male	PPM	11(27)	22(53)	4(10)	4(10)	0.5[x]
Female		4(21)	10(53)	4(21)	1(5)	
Male	SPM	7(17)	12(29)	19(47)	3(7)	0.1[x]
Female		1(5)	3(16)	13(68)	2(11)	

[x]p>0.05

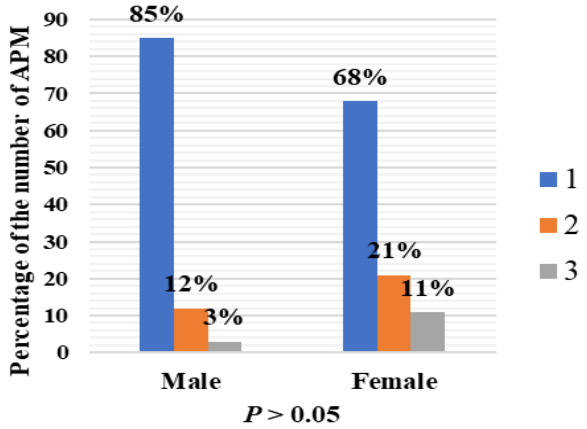

Figure 2: Number of the APM of the right ventricle in male and female

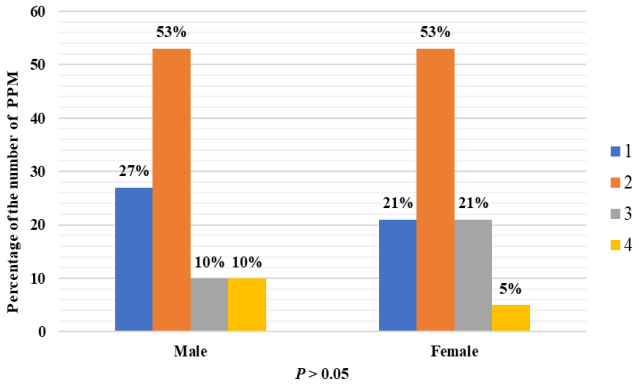

Figure 3: Number of the PPM of the right ventricle in male and female

b. Number of the PPM

Table 1 and figure 3 demonstrates the number of single, double, triple and quadruple PPM were 27%, 53%, 10% and 10% for male groups and 21%, 53%, 21% and 5% for female groups 53% of 2 posterior papillary, 27% of 1 posterior papillary, 10% of 3 posterior papillary in male. The comparison between groups (A and B) was not statistically significant (P > 0.05).

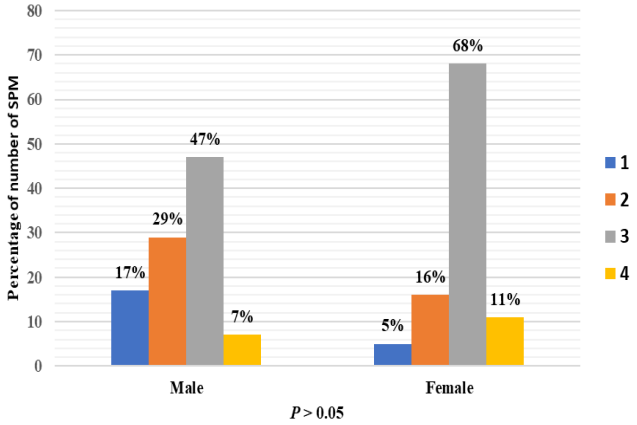

Figure 4: Number of the septal papillary muscles (SPM) of the right ventricle in males and females.

c. Number of the septal papillary muscle

Table 1 and figure 4 reveals in group A and group B there were 17%, 29%, 47%, 7% and 5%, 16%, 68%, 11% single, double, triple and quadruple numbers of SPM respectively. The statistical analysis exhibited a non-significant difference in the number of SPM in-between group A and group B (P > 0.05).

There were no quadruple numbers of APM for both groups whereas the highest number of papillary muscles belonged to PPM and SPM for both genders.

Discussion

The number of different papillary muscles in the right heart are inconstant and clinically significant. Papillary muscles play a significant role in right ventricular contraction by elongating the tricuspid valve annulus in the direction of the apex, resulting in a reduction of the long axis and the chamber becoming sphere-shaped for the ejection of blood to the pulmonary circulation. [9]

Our findings regarding the number of APM is consistent with that done by Parvatha et al in 2014 that revealed single APM in 85% and double APM in 10% of cases. [8] Another study that was done by Nigri et al. also showed single and double numbers of APM in 81% and 19% of cases respectively [10] which is almost similar to our observations. At the same time among 96 samples, Harsha et al. demonstrated 1, 2 and 3 numbers of APM in 68.8%, 25% and 6.3% correspondingly. This is parallel to our study in terms of frequency of single APM though the percentage

is dissimilar. Moreover, his observations about PPM and SPM were not similar to our present study and most probably the study conducted among different ethnicities. [3] But near similarity noted with the research done by Begum et al who also conducted her research among the Bangladeshi population. [11]

PPM double number were more common, and we found more triple SPM in our study for both genders. Our discovery is in the line with the findings of Begum et al. [11] and Aktas et al [12] but dissimilar with James et al, Harsha et al. [3, 13]. Because their study of methodology and layout was a different study.

Another study conducted by Anubha et al. on 52 formalin-fixed normal cadaveric heart observed three papillary muscles (23.07%). APM was present in all hearts, but PPM and SPM were found in 15.38% and 55.76%, respectively. The author reported dual and triple papillary muscles, which supports our findings. [14]

This study revealed that APMs were unique, PPMs can be single, double, triple and quadruple. The septal papillary muscle was variable and miniature in size. [15, 16] There was great inconsistency in the numbers of different papillary muscles in different studies. The maximum number of papillary muscles in our research was 4 that belonged to PPM and SPM. Whereas the highest frequency was 9 and 10 in numbers detected by Aktas et al. and Harsha et al. from Turkey and India respectively [3, 12] which may have been varied due to geographic and ethnic variations.

Conclusion

Morphological variation of papillary muscles is one of the reasons for myocardial infarction in the current period. Thus, it is important to know both the normal anatomy and clinical variations of papillary muscles. Morphological discrepancies of papillary muscles provide additional information to our clinicians which will be useful for identifying in modern surgical techniques such as papillotomy and commissurotomy in rheumatic heart disease, leaflet resection in myxomatous lesions, removal of vegetation, transfer and rotation of leaflet segment. Awareness of flexibility of papillary muscles is useful for interventional or surgical correction of congenital heart diseases like Ebstein's disease dysplasia, the discrepancy in the attachments of muscle, their morphology or their absence may produce prolapse of the leaflets. So proper knowledge of anatomical variations of papillary muscle is more necessary for tricuspid valve repair, replacement as well as invasive valvuloplasty.

Our research will help us to know about the tricuspid valve and papillary muscles morphology. It will also support different surgical and cardiac interventional treatments. For this purpose, a comprehensive examination of the heart valve and its complexity should be carefully performed to clarify the reason for sudden death with no apparent cause.

The present study will give us baseline data concerning variations of the papillary muscles of the right ventricle in the Bangladeshi population including both genders and it will help to provide definite outlay for administration & provides further information to the clinicians, cardiologists, anatomists, and physiologists which will help them in deciding the identification and management of different diseases.

Limitation and future scope

The cadaveric heart was obtained from mortuaries, (DMC and SSMC) after 24-48 hours of death, so the authors were not able to confirm any pre-existing heart diseases such as hypertension, heart failure, and cardiomegaly. The authors humbly acknowledge getting equal numbers of male and female cadaveric hearts as a pitfall. The present study gives suggestions for further researchers to collect more fresh heart samples.

Abbreviations

Anterior papillary muscle (APM), atrioventricular (AV), papillary muscles (PM), posterior papillary muscle (PPM) Septal papillary muscle (SPM)

Acknowledgment

Authors are thankful to the Forensic Medicine Department, Anatomy Department of DMC and SSMC, Dhaka, Bangladesh.

Authors' contribution

a. Study planning: LS, HN
b. Data collection: LS
c. Data analysis/ interpretation: SK, AST, TB, HN
d. Manuscript writing: LS, SK
e. Manuscript revision: SK, AAK
f. Final approval: LS, SK, AAK, AST, TB, HN
g. Agreement to be accountable for all aspects of the work: LS, SK, AAK, AST, TB, HN

Funding

This research has not received any grant or funding from agencies in the public domain, commercial, or not-for-profit sector.

Availability of data and materials

All data underlying the results is available as part of the article, and no additional source data is required.

Competing interests

None declared.

Publisher's Note

QIU remains neutral with regard to jurisdictional claims in published maps and institutional affiliations. The

publisher shall not be legally responsible for any types of loss, actions, claims, proceedings, demand or costs or damages whatsoever or howsoever caused arising directly or indirectly in connection with or arising out of the use of this material.

References

1. Datta AK. Essentials of human anatomy (thorax and abdomen) 9th ed. Kolkata: Current books International. 2014; 9:174-98.
2. Richard Drake A. Wayne Vogl Adam Mitchell. Gray's Anatomy for Students. Elsevier. 2014; 3.
3. Harsha BR, Dakshayani KR. Morphometric Study on Papillary Muscles of Human Tricuspid Valve. International Journal of Anatomy and Research. 2014; 3(1):865-68. https://doi.org/10.16965/ijar.2015.103
4. Xanthos T, Dalivigkas I, Ekmektzoglou KA. Anatomic variations of the cardiac valves and papillary muscles of the right heart. Ital J Anat Embryol. 2011;116(2):111-26.
5. Hetzer R, Drews T, Siniawski H, Komoda T, Hofmeister J, Wenig Y. Preservation of papillary muscles and chordae during mitral valve replacement: possibilities and limitations. J Heart Valve Dis 1995; 4 (Suppl 2): 115-23.
6. Lang P, Oberhoffler R, Cook A. Pathologic spectrum of malformations of the tricuspid valve in prenatal and neonatal life. J Am Coll Cardiol.1991; 17:1161-67. https://doi.org/10.1016/0735-1097(91)90848-4
7. Shperling ID. Papillary-chordal insufficiency of the cardiac atrioventricular valves. Arkh Patol. 1980;42:23-6.
8. Priya P, Rajila HS, Aruna S, Karunagaran, Veerappan V. Study on Variations in the Anterior Papillary Muscle of the Right Ventricle. International Journal of Innovative Research and Development. 2014; 3(3):416-9.
9. Joudinaud TM, Flecher EM, Duran CMG. Functional terminology for the Tricuspid valve. J Hear Valve Dis. 2006; 15(3):382-8.
10. Negri GR, Didio LJA, Baptista CAC. Papillary muscles and tendinous chords of the right ventricle of the human heart morphological characteristics. Surg Radiol Anat. 2001; 23:45-9. https://doi.org/10.1007/s00276-001-0045-7
11. Begum JA, Khalil M, Rahman H, Adiluzzaman AA. A morphological and morphometric study of the right ventricular papillary muscles of autopsied heart of Bangladeshi people. Mymensingh Medical Journal. 2006; 15(2):131-4. https://doi.org/10.3329/mmj.v15i2.30
12. Aktas EO, Govsa F, Kocak A, Boydak B, Yavuz IC. Variations in the papillary muscles of normal tricuspid valve and their clinical relevance in medicolegal autopsies. Saudi Medical Journal. Saudi Med J. 2004; 25(9): 1176-85.
13. James TN, Sherf L, Schlant RC, Silverman ME. Anatomy of the heart. In: Hurst JW, editor. The heart. New York: McGraw-Hill Book Company. 1982; 5:p. 24.
14. Saha A, Roy S. Papillary muscles of right ventricle-morphological variations and its clinical relevance. Cardiovasc Pathol. 2018; 34:22-7 https://doi.org/10.1016/j.carpath.2018.01.007
15. Gheorghitescu (Janca) Ruxandra, Toba M, Iliescu DM, Bordei P. Morphological features of papillary muscles in the right ventricle. ARS Medica Tomitana. 2016;22(3):135-44. https://doi.org/10.1515/arsm-2016-0023
16. Farzana T, Khalil M, Mannan S, Sultana J, Sumi MS, Sultana R. Length of papillary muscles in both ventricles of different age group on Bangladeshi cadaver. Mymensingh Med J. 2015; 24(1):52-8.